



Pathomorphological changes of flunixin meglumine toxicity in layer chicks

R. A. Patel, K. B. Kapadiya* and D. J. Ghodasara

Department of Veterinary Pathology, College of Veterinary Science and Animal Husbandry, Anand Agricultural University, Anand-388110 (Gujarat), INDIA

*Corresponding author. E-mail: komalkapadiya89@gmail.com

Received: October 04, 2015; Revised received: April 29, 2016; Accepted: July 18, 2016

Abstract: The aim of the 21 day toxicity study was to evaluate the pathomorphological effect of flunixin meglumine in layer chicks. The chicks of Group I were kept as control while groups II, III and IV were fed with diet containing flunixin meglumine @ 10 ppm, 25 ppm and 50 ppm respectively for 21 days. Clinical signs viz. anorexia, dullness, lethargy, lameness and uneven growth were noticed in chicks of treatment groups III and IV only. Maximum mortality was observed in group IV (12%) followed by group III (4%). A dose dependant reduction in body weight was observed in all the treatment groups. The mean values of Kidney: Body weight ratio was significantly increased in group IV. The plasma uric acid, creatinine and BUN values were significantly increased in group III whereas increase in group IV was highly significant. Grossly, there was deposition of chalky white urates on serosal surface of kidney, heart and liver in chicks of group IV which died during experiment. Microscopically, lesions were characterized by varying degrees of congestion, haemorrhages, degeneration, necrosis and deposition of urate crystals in visceral organs of group III and group IV chicks. The intensity and distribution of pathological lesions were more severe in chicks of group IV, followed by chicks of group III. The overall lesions gave an impression that flunixin meglumine was nephrotoxic in nature.

Keywords: Flunixin meglumine, Nephrotoxicity, Urate crystals, Visceral gout

INTRODUCTION

Diclofenac, a non-steroidal anti-inflammatory drug (NSAID) was the only cause of rapid decline in vulture population across the Indian subcontinent (Oaks *et al.*, 2004). Surveys of livestock carcasses across India indicate that over 10% contained diclofenac residue that occur at sufficient concentrations, in relation to dose dependent mortality of Oriental white backed vultures (*Gyps bengalensis*) (Naidoo *et al.*, 2009). Scientific evidences following the observation of waste disposal practices of carcasses confirmed without any doubt that the veterinary use of diclofenac is the main cause of decline in vulture population throughout the Indian subcontinent (Green *et al.*, 2004). Thus, Government of India banned diclofenac in veterinary use from May, 2006 due to vulture crisis. After the ban of diclofenac in veterinary field other NSAIDs such as ketoprofen, meloxicam, flunixin meglumine, carprofen, phenylbutazone *etc.* are now commonly used in veterinary practice. Diclofenac, and now ketoprofen, have been clearly shown to be toxic to Gyps vultures, and carprofen and flunixin are also likely to be toxic (Cuthbert *et al.*, 2006). Flunixin, 2-(2-methyl-3-trifluoromethylenilino) nicotinic acid, is a non-steroidal anti-inflammatory agent that is a highly substituted derivative of nicotinic acid. In veterinary medicine, it is used with meglumine as a solubilizer as flunixin meglumine. As flunixin meglumine has anti-inflammatory, analgesic and antipyretic

properties, it has been used extensively alone or in combination with antimicrobial agents to treat a number of conditions in domestic animals like lameness, colic, endotoxemia, mastitis, metritis and respiratory diseases. This suggests that flunixin meglumine may be potential alternative of diclofenac for veterinary use.

This highlights need for robust safety testing before recommending any NSAIDs as a safe replacement for diclofenac (Swan *et al.*, 2006). Poultry feed also contain many animal source byproducts like meat and bone meal, blood meal, bone based DCP, mutton tallow *etc.* which are likely to have flunixin meglumine residue and probably responsible for visceral gout in layers. Therefore, the aim of this study was to evaluate whether the flunixin meglumine can be used in animals as an alternative to diclofenac, without serious toxicity in vultures and poultry.

MATERIALS AND METHODS

Experimental birds: A total of 100 apparently healthy day old BV-300 layer chicks (*Gallus domesticus*) were procured from a local commercial hatchery (Shakti hatcheries, Sarsa, Anand, Gujarat, India) and were maintained at Experimental unit, Department of Veterinary Pathology, College of Veterinary science and Animal husbandry, Anand under standard managemental conditions. The chicks were given feed and fresh water *ad libitum*.

Experimental design: Chicks were randomly divided into 4 equal groups. Chicks were fed graded dose of FM (Virbac animal health India Pvt. Ltd., Mumbai, Batch No. VB107) through dietary inclusion for 21 consecutive days at the dose rate of 10, 25 and 50 mg/kg (ppm) of feed in group II, III and IV respectively, while group I was offered feed free of FM and served as control. All the birds were observed daily for any abnormal physical or behavioural changes and mortality throughout the period of 21 days of experiment. Weight of chicks was recorded at day 1 and at the end of every week. At the end of experiment i.e. on 22nd day, about 2 ml blood was collected from jugular vein in vacutainer having K₃EDTA (1-2 mg/ml) as an anti-coagulant for plasma separation. Plasma samples were stored in deep freeze at -20^oC for uric acid, creatinine and BUN estimation. After the blood collection all the surviving birds in all four groups were subjected to a terminal sacrifice. Detailed post mortem examination was performed on sacrificed and dead birds. The gross pathological lesions were recorded and for histopathological examination, tissue from kidney, liver, heart, lung, spleen, proventriculus and intestine were collected in 10% formalin. Pieces of kidney, liver and heart tissues were also fixed in absolute alcohol for De-Galantha's special staining for demonstration of urate crystals.

RESULTS AND DISCUSSION

Clinical signs: Chicks under group I and II did not reveal any observable clinical signs during the entire experimental period. Birds in the group III and IV showed similar clinical signs with gradually more pronounced in group IV. Birds exhibited a tendency to remain standing at one place with apathy, dullness and drooping of the wings. Birds appeared emaciated, dehydrated, depressed and lethargic with shrunken eyes. They also exhibited clinical signs like anorexia and uneven growth.

Muhammad *et al.*, (2012) noticed signs of depression, anorexia, lethargy and reluctance to move in FM treated broiler birds. They showed stiff gait and felt difficulty in walking and standing. Affected birds perched aside with ruffled feathers and eyes closed. Prior to death affected birds became comatose. The

Table 1. Mortality and Kidney: Body weight ratio (Mean ± SE, ×10⁻³) of layer chicks of different experimental groups at the end of treatment period.

Experimental Group	No. of layer birds died	Mortality %	Kidney: Body weight ratio
I	0	0	7.763 ± 0.104
II	0	0	8.017 ± 0.133
III	1	4	8.192 ± 0.470
IV	3	12	9.380 ± 0.629*
Total deaths	4		

*: Significant (p < 0.05) as compared to control.

Table 2. Weekly body weight (Mean ± S.E., g) in layer chicks of different experimental groups.

Day	Group - I	Group - II	Group - III	Group - VI
0	36.16±0.28	36.4±0.31	35.08±0.43	35.68±0.31
7	60.46±0.70	59.52±0.80	58.82±0.55	56.22±0.55
14	100.2±0.71	98±0.75	97.3±0.88*	83.84±1.54**
21	163.33±2.41	160.97±1.53	159.43±1.34*	143.73±1.69**

*: Significant (p < 0.05); **: Highly significant (p < 0.01)

Table 3. Average feed conversion ratio (FCR), feed consumption (g) and body weight (g) in different experimental groups at end of experiment.

Experimental Group	Feed consumption (g)	Body weight (g)	FCR
I	290.62	163.33	1.77
II	289.67	160.97	1.79
III	288.00	159.43	1.80
IV	263.65	143.73	1.83

Table 4. Mean values of plasma uric acid (mg/dl), creatinine (mg/dl) and BUN (mg/dl) in layer chicks of different experimental groups.

Experimental Group	Uric acid (mg/dl)	Creatinine (mg/dl)	BUN (mg/dl)
I	6.105±0.17	0.28±0.02	1.74±0.07
II	7.005±0.18	0.38±0.05	1.88±0.07
III	8.55±0.12*	0.39±0.06*	1.92±0.09*
IV	10.67±0.56*	0.91±0.06*	2.68±0.08**

*: Significant (p < 0.05); **: Highly significant (p < 0.01)

present experiment indicated that the compound FM could produce clinical signs like dullness, dehydration, anorexia, uneven growth, ruffled feather, lethargy and shifting leg lameness were in agreement with the findings of Muhammad *et al.*, 2012.

Mortality : Maximum mortality was observed in group IV (12%) followed by group III (4%) (Table 1). Mortality in group IV was observed on 15th and 16th day whereas in group III it was on 16th day of experiment.

Cuthbert *et al.*, (2007) documented that carprofen and FM were associated with mortality of *Gyps* vultures and other species, with a reported mortality of 13% (5/40 cases) and 30% (7/23 cases), respectively as a result of renal failure and/or visceral gout, in a surveys of veterinarians and zoos document on treatment with NSAIDs. Muhammad *et al.*, (2012) reported 20%, 40% and 60% mortality in five weeks old broiler chickens treated with FM at the dose rate of 2.5, 5 and 10 mg/kg body weight for four consecutive days, intramuscularly. The mortality observed in present experiment was in agreement with report of earlier workers (Muhammad *et al.*, 2012; Cuthbert *et al.*, 2007). The mortality in case of layer birds found in the present study is less than mortality observed in case

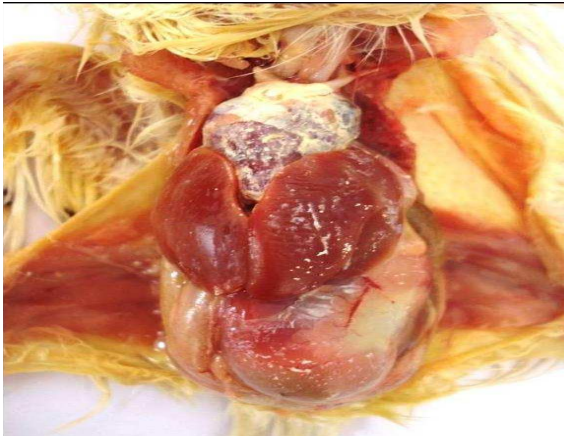


Fig. 1 Layer chick died from group IV showing chalky white urate deposition on surface of pericardium and liver.

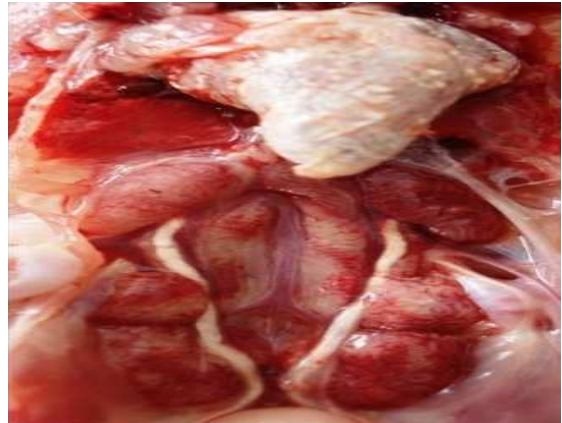

Fig. 2. Gross lesions in kidney of group IV bird died during experiment. Pale enlarged, frosted kidney and dilated urters filled with uric acid crystals. Heart presents marked deposition of urate crystals.

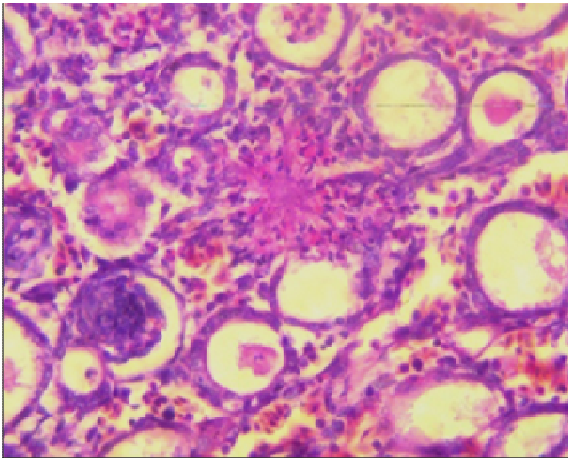


Fig. 3. Section of kidney from group IV dead chick showing radiating rosette shaped uric acid crystal. H&E stain X 300.

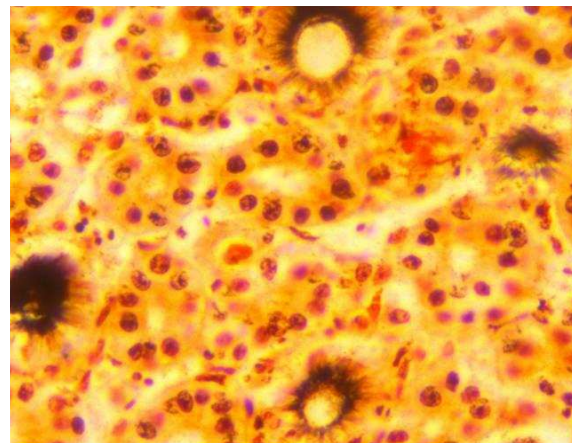


Fig. 4 Section of kidney from group IV dead chick showing radiating rosette shaped uric acid crystals. De Galantha's stain X 300.

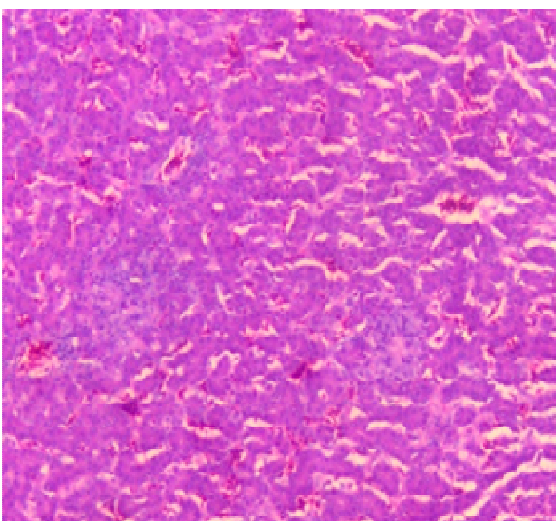


Fig. 5 Section of liver from group IV dead chick showing radiating rosette shaped uric acid crystals surrounded by inflammatory cells. H & E stain X 150.

of study of Muhammad *et al.*, (2012). This indicates that layer birds are more resistant to toxicity of flunixin meglumine as compared to broilers.

Body weight: The reduction in body weight was found in group III and IV chicks. At the end of 2nd and 3rd week group III and IV showed significant and highly significant decrease in body weight respectively, as compared to control (Table 2).

Seema (2006) studied age related pathological effects of diclofenac sodium in poultry and observed significant reduction in average body weight in all treatment groups of Cobb 100 broiler chicks as compared to control group, while, in White leghorn (WLH) chicks, reduction in body weight was noticed only in high dose (150 ppm diclofenac sodium) group. Irtaza *et al.*, (2008) observed that body weight of birds on day 7 of the experiment did not differ significantly, but on day 21 of the experiment, it decreased significantly in broilers and pigeons of all diclofenac treated groups. The present observation of decrease in body weight

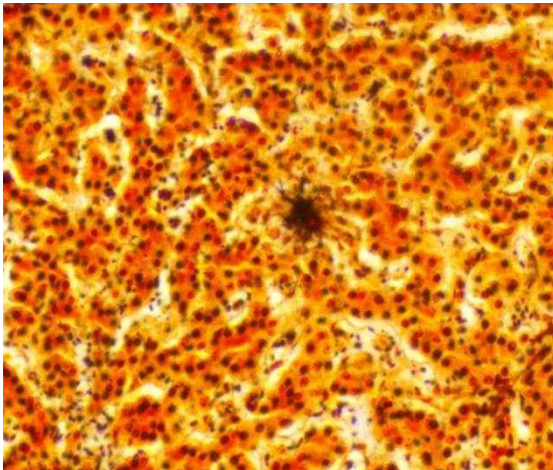


Fig. 6. Section of liver from group IV dead chick showing uric acid crystal in radiating rosette pattern. De Galantha's stain X 150.

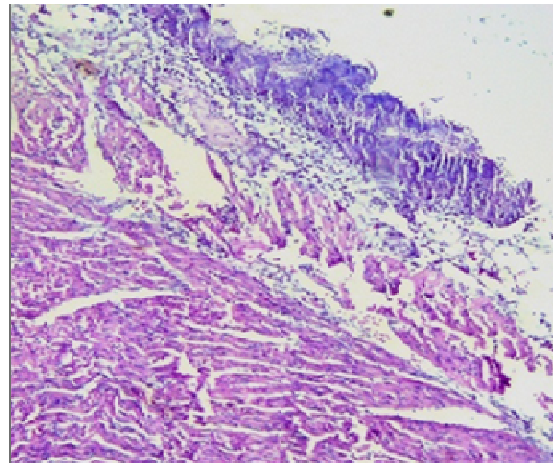


Fig. 7. Section of heart from group IV dead chick showing amorphous deposition of uric acid crystal on pericardium of heart. H & E stain X 150.

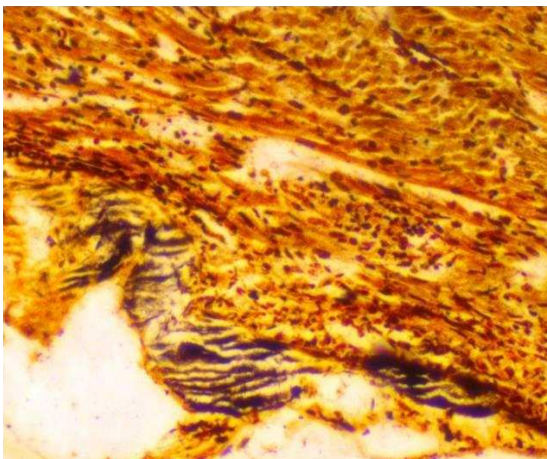


Fig. 8. Section of heart from group IV dead chick showing amorphous deposition of uric acid crystal on pericardium of heart. De Galantha's stain X 150.

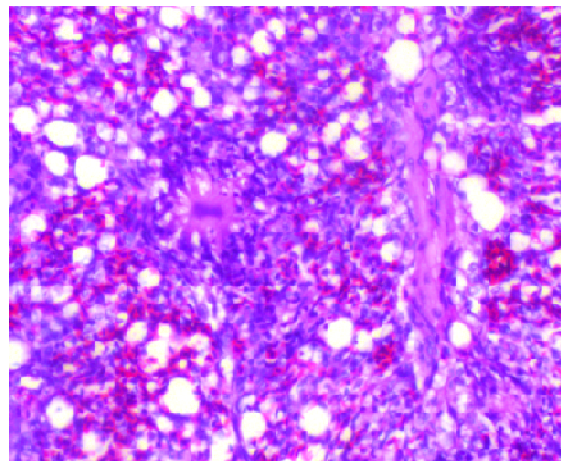


Fig. 9. Section of lung from group IV dead chick showing congestion and deposition of radiating rosette shaped uric acid crystal. H & E stain X 300.

was in support of observations made by other authors (Irtaza *et al.*, 2008; Seema, 2006) during their diclofenac toxicity studies in broilers.

Feed consumption and feed conversion ratio (FCR): Marginal reduction in feed consumption was observed in group IV followed by group III and II as compared to control at the end of experiment (Table 3). The average FCR calculated at the end of experiment was higher in treatment groups as compared to the control. Highest FCR of 1.83 was observed in group IV followed by 1.80 in group III, 1.79 in group II and lowest 1.77 was recorded in group I.

Shinde, (2008) observed increase in feed conversion ratio in all treatment groups than control in a study of diclofenac sodium toxicity in broiler chicks. Increased FCR during the present study was due to marginal reduction in feed consumption and subsequent negative effect of flunixin meglumine on body weight gain was in support of observations made by Shinde, 2008.

Kidney: body weight ratio: The mean values of Kidney: Body Weight ratio was significantly increased in group IV as compared to control (Table 1).

Seema (2006) noticed that mean kidney: body weight ratios were higher in all treatment groups as compared to control group in age related pathological effects of diclofenac sodium treatment in poultry. The results of increase in kidney:body weight ratio were in alliance with Seema, 2006 in her diclofenac toxicity study in broilers. The present study suggested that mean kidney:body weight ratio was higher due to reduced body weight and uric acid crystals deposition in kidney of group IV birds.

Plasma biochemical parameters: Increased mean values of plasma uric acid, creatinine and BUN were noticed in all treatment groups as compared to control (Table 4). The chicks of group III revealed significant and chicks of group IV revealed highly significant increase in plasma uric acid, creatinine and BUN as compared to the control group.

The biochemical investigation revealed that the increase in level of uric acid and creatinine were in support of observations made by Muhammad *et al.*, 2012. Muhammad *et al.*, (2012) reported that the broiler birds that died due to FM toxicity, exhibited several fold increase in serum uric acid concentration. Before death, serum uric acid concentration ranged from 40-80 mg/dL. Serum creatinine values increased in the same birds which showed rise in serum uric acid. Thus there appeared to be a causal relationship between an increase in uric acid and flunixin lethality in birds.

Flunixin meglumine induced gout in birds is caused by renal failure and is analogous to hyperuremia. Kidneys failed to remove the uric acid efficiently from the blood and tissues which became super saturated with uric acid, resulting in urate salt precipitation as crystals and cellular reactions to uric acid crystals deposition causing gout.

Pathomorphology: Grossly, white dry foci of urate deposition were found on visceral organs like liver, kidney and heart of chicks died during experiment from group IV (Fig. 1).

Kidney: Gross lesions in kidney were found only in the birds died during the experiment from the treatment groups III and IV. Kidneys of the chick from group III which died during experiment were pale, swollen with dilated tubules filled with uric acid crystals while kidneys of the chicks from group IV died during experiment were more enlarged and frosted with pin point haemorrhages on the surface with ureters filled with uric acid crystals (Fig. 2). No gross lesions were observed in kidneys of birds sacrificed at the end of experiment.

Histopathological lesions in kidney were degenerative and necrotic in nature. Lesions were observed in kidneys of birds of group III and IV which died during experiment. Histopathological lesion in the chick of group III which died during experiment includes congestion, cystic dilatation and degeneration of renal tubular epithelium with tubular necrosis. Microscopic changes in kidney of chicks from group IV that died during experiment were more extensive with severe congestion, degeneration and necrosis. There was also cystic dilatation of renal tubules, glomerular atrophy and desquamation of renal tubular epithelium. Further these lesions were also manifested by deposition of radiating rosette shaped uric acid crystals in parenchyma (Fig. 3). These rosette shaped uric acid crystals appeared black in colour with De Galantha's stain (Fig. 4). The chicks sacrificed at the end of the experiment from all the treatment groups did not reveal any remarkable histopathological lesions including mid and the high dose group.

Liver: Grossly, liver from group IV dead chicks were enlarged, soft in consistency and congested. Surface of liver showed slight deposition of chalky white uric acid crystals (Fig. 1). No appreciable changes in the liver of chick died during experiment from group III

were observed. Chicks sacrificed at the end of the experiment from all the treatment groups including high dose group did not reveal any gross changes in liver.

Microscopically, section of liver from chick of group III that died during experiment showed only mild congestion. Chicks from group IV which died during experiment showed congestion along with deposition of radiating rosette shaped uric acid crystal surrounded by mononuclear cells (Fig. 5). Uric acid deposits in section of liver from group IV chicks died during experiment appeared black in colour with De Galantha's stain (Fig. 6). No appreciable changes were detected in liver of chicks terminally sacrificed from all the treatment groups including high dose group.

Heart : Gross lesions in heart included deposition of chalky white urate deposition on the surface of pericardium. This deposition was mild in the chick from group III that died during experiment while group IV chicks died during experiment revealed marked deposition of white chalky urate on the surface of heart (Fig. 1). No appreciable gross changes were found in the chicks sacrificed at the end of the experiment from any treatment groups.

Microscopically, chicks from group IV which died during experiment revealed urate deposition in the myocardium. Pericardium of the heart showed marked thickening with urate deposition (Fig. 7). Amorphous urate deposition on pericardium appeared black in colour with De Galantha's stain (Fig. 8). No appreciable histopathological changes were found in the chick that died during experiment from group III. Chicks sacrificed at the end of experiment from all the treatment groups including high dose group did not reveal any histopathological lesion.

Spleen: Grossly, no appreciable changes were observed in group II & group III chicks. Spleen of the birds from group IV that died during experiment was congested, enlarged and showed slight deposition of urates on its capsule.

Sections of spleen from chicks of group II & III did not revealed any histopathological changes. Spleen showed congestion and deposition of uric acid tophi in splenic parenchyma in chicks which died during experiment from group IV.

Lung: Grossly, no appreciable changes were observed in group II & III chicks. Lungs were congested in many cases in group IV. Birds from group IV that died during the experiment showed mild deposition of urate on lungs. Histopathologically, no appreciable changes were observed in group II & group III chicks. Chicks from group IV that died during experiment revealed congestion and focal deposition of urate crystals in lung parenchyma which was surrounded by inflammatory cells (Fig. 9). The chicks sacrificed at the end of experiment from group IV revealed only mild congestion.

Intestine: Grossly, no appreciable changes were observed in group II & III chicks. Lesions in intestine were present

in chicks which died during experiment from treatment groups IV. These were in the form of deposition of white urate crystals over serosal surface of intestine.

Microscopically, no appreciable changes were observed in group II & group III chicks. Serosal surface of intestine was congested in died chick from group IV.

Air sacs: The birds that died due to visceral gout revealed urate deposition on air sacs that were more prominent on abdominal air sacs. Lesions were mild to moderate in group IV and characterized by focal to diffuse urate deposition in air sacs giving opaque white membranous appearance.

Joints: Grossly, no appreciable changes were observed in joints of group II, III and IV chicks which were sacrificed at the end of experiment. Chicks from group IV that died during experiment revealed deposition of uric acid crystals in hock and phalangeal joints. White urates depositions were observed on articular surface of hock joint in chicks from group IV that during experiment.

The layer chicks exposed to flunixin meglumine at three different dose levels revealed dose dependant pathological changes in different organs. Grossly, there was deposition of chalky white urates on the surface of visceral organs is in agreement with the observations made by various workers (Muhammad *et al.*, 2012; Sharma and Vegad, 2010). Muhammad *et al.*, (2012) reported that the precipitation of urates varied from multifocal to locally extensive areas present in subcutaneous tissues of abdominal and cervical region, pectoral and thigh muscles, air sacs, pericardium, epicardium, sternum, abdominal fat, serosal surface of liver spleen, proventriculus, ventriculus, entire intestinal tract, kidneys and articular surfaces within hip and hock joints. Small uroliths were found in segments of urethra and urethral openings of the cloaca. The liver was friable and kidneys were pale-tan and swollen. Varied amount of white debris and fibrin were scattered on most of the visceral serosa. Sharma and Vegad (2010) grossly observed irregular and excessive enlargement of kidney lobules and chalky white urate crystals deposition all over the visceral organs like the heart, liver, kidney, gizzard and intestines, and even in the tissues of thigh in gouty birds.

Microscopically varying degree of congestion, haemorrhage, degeneration, necrosis and deposition of urate crystals in kidney, Liver, heart, spleen, lung were also reported by earlier workers (Muhammad *et al.*, 2012; Klein *et al.*, 1994). Histopathological findings of kidney damage due to flunixin meglumine toxicity were in agreement with the observations made by various workers (Muhammad *et al.*, 2012; Klein *et al.*, 1994; Hocking *et al.*, 2005; Clyde and Paul-Murphy, 1999). Muhammad *et al.*, (2012) observed multifocal deposition of urate tophi extending into the adjacent cortical interstitium, frequently surrounded by inflammatory cells and cellular debris. Multifocal cystic dilatation of renal tubules, with tubular epithelial degeneration and

presence of proteinacious tubular cast were also reported in kidney sections of chickens treated with FM. Klein *et al.*, (1994) and Hocking *et al.*, (2005) reported renal lesions as acute necrotizing glomerulonephritis with urate tophi in renal tubules in Bobwhite quail treated with FM. Clyde and Paul-Murphy (1999) also reported renal ischemia and necrosis in Siberian cranes treated with FM at the dose rate of 5 mg/kg.

The intensity and distribution of pathological lesions were dose dependent. Histopathological findings of the present study in kidneys are corresponding with the biochemical finding like increased levels of plasma uric acid, creatinine and BUN which causes decrease in glomerular filtration rate of flunixin meglumine and its metabolite from kidney, leading to kidney lesions and ultimately visceral gout. The overall lesions gave an impression that flunixin meglumine was nephrotoxic in nature.

The biochemical alterations and pathological changes observed during the present investigation were similar to that of diclofenac toxicity in vultures in Indian sub-continent. It was presumed that treating livestock with flunixin meglumine might have similar residual toxicity of diclofenac to the vultures.

Conclusion

Flunixin meglumine induces toxicity symptoms in layer chicks when administered at dose rate of more than 25 ppm for the period of 21 days. Layer chicks showed reduction in body weight gain. The layer chicks administered 50 ppm of flunixin meglumine showed significant increase in kidney: body weight ratio, reduced feed consumption and an increased FCR. Layer chicks from treatment group III showed significant and from group IV showed highly significant increase in serum biochemical parameters viz. uric acid, creatinine and BUN. Flunixin meglumine \geq 25 ppm of feed caused tubular degeneration, necrosis, congestion, glomerular atrophy, dilatation of tubules and deposition of uric acid crystals as evident by De Galantha's staining. Flunixin meglumine is nephrotoxic and causes visceral gout in layer chicks as evident by pathomorphological and serum biochemical parameters.

ACKNOWLEDGEMENTS

The authors are thankful to the Dean, Veterinary College, Anand, Gujarat for providing necessary facilities and departmental staff for technical and general support.

REFERENCES

- Clyde, V.L. and Paul-Murphy, J. (1999). Avian analgesia. In: Fowler ME, Miller RE. Zoo and Wild Animal Medicine. *Current Therapy*. Philadelphia. pp 309-314.
- Cuthbert, R., Parry-Jones, J., Green, R.E. and Pain, D.J. (2006). NSAIDs and scavenging birds: potential impacts beyond Asia's critically endangered vultures. *Biology Letters*, 3:90-93.

- Cuthbert, R., Parry-Jones, J., Green, R.E. and Pain, D.J. (2007). NSAIDs and scavenging birds: Potential impacts beyond Asia's critically endangered vultures. *Biology Letters*, 3: 90-93.
- Green, R.E., Newton, I., Shultz, S., Cunningham, A.A., Gilbert, M., Pain, D.J. and Prakash, V. (2004). Diclofenac poisoning as a cause of vulture population declines across the Indian subcontinent. *J. Appl. Ecol.*, 41: 793-800.
- Hocking, P.M., Robertson, G.W. and Gentle, M.J. (2005). Effect of non-steroidal anti-inflammatory drugs on pain-related behavior in a model of articular pain in the domestic fowl. *Res. Vet. Sci.*, 78: 69-75.
- Irtaza, H., Khan, M. Z., Khan, A., Ijaz, J. and Kashif, M. S. (2008). Toxicological effects of diclofenac in four avian species. *Avian Pathol.*, 37(3): 315-321.
- Klein, P.N., Charmatz, K. and Langenberg, J. (1994). The effect of flunixin meglumine (Banamine) on the renal function in northern bobwhite (*Colinus virginianus*): an avian model. *Proc. Am. Assoc. Zool. Vet.*, pp: 128-131.
- Muhammad, R., Muhammad, A. and Khawaja, T.M. (2012). Toxicity of flunixin meglumine in broiler chickens. *J. Pharm. Sci. & Res.*, 4(2): 1748-1754.
- Naidoo, V., Wolter, K., Cromarty, D., Diekmann, M., Duncan, N., Meharg, A.A., Taggart, M.A., Venter, L. and Cuthbert, R. (2009). Toxicity of non-steroidal anti-inflammatory drugs to Gyps vultures: a new threat from ketoprofen. *Biol. Lett.* 6: 339-341.
- Oaks, J.L., Gilbert, M., Virani, M.Z., Watson, R.T., Meteyer, C.U., Rideout, B., Shivaprasad, H.L., Ahmed, S., Chaudhry, M.J.I., Arshad, M., Mahmood, S., Ali, A. and Khan, A.A. (2004). Diclofenac residues as the cause of population decline of white-backed vultures in Pakistan. *Nature*, 427: 630-633.
- Seema, A. (2006). M.V.Sc. thesis. Age related pathological effects of diclofenac sodium in poultry. Anand Agricultural University, Anand.
- Sharma, R. and Vegad, J.L. (2010). Avian gout: causes, treatment and prevention. *Poultry line.*, 10(8): 19-21.
- Shinde, A.S. (2008). M.V.Sc. thesis. Pathomorphological and immunobiochemical studies on induced diclofenac sodium toxicity in broiler chicks (*Gallus gallus domesticus*), Sardarkrushinagar Dantiwada Agricultural University, Dantiwada.
- Swan, G.E., Naidoo, V., Cuthbert, R., Green, R.E., Pain, D.J. Swarup, D., Prakash, V., Taggart, M., Bekker, L., Das, D., Diekmann, J., Diekmann, M., Killan, E., Meharg, A., Patra, R.C., Saini, M. and Wolter, K. (2006). Removing the threat of diclofenac to critically endangered Asian Vultures. *PLoS Biol.*, 4: 1-8.